



PATIENT

Sofie Johnson

SPECIES

Canine

BREED

Pomeranian

SEX

Female Spayed

AGE

11 years

WEIGHT

6.5 lbs

INTERPRETED BY

Maggie Machen
 Lamy, DVM, DACVIM
 (Cardiology)

IMAGING PERFORMED BY

Sara Hansen

HOSPITAL NAME

Willakenzie Animal
 Clinic

REFERRING VET

Dr. Kairis

INVOICE

28028

DATE

12/30/22

PRESENTING CLINICAL SIGNS

History: Grade 2/6 systolic murmur on exam. Coughing and panting at night noted by client. Assess prior to dental. Sedated with Torb.
 -Abnormal PE/Chem/CBC/UA Results: Platelets - 691 (143-448) SDMA 16 (0-14) BUN: 34 (9-31)

RADIOGRAPHIC FINDINGS *NOTE: Images submitted for supplemental cardiac information only.
 Mild cardiomegaly. No obvious evidence of CHF.

ELECTROCARDIOGRAPHIC FINDINGS *Note: Single lead ECGs are evaluated as a rhythm strip. Morphology/MEA cannot be definitively commented on.
 A single lead ECG is available; 50mm/s, 10mm/mV. The average heart rate is 90bpm (range 60-166bpm). The rhythm is sinus in origin, with a p for every QRS complex and vice versa. The P and QRS morphologies are positive. No ectopic beats, pauses or dysrhythmias observed.
 ECG diagnosis: Normal sinus rhythm with profound respiratory variation.

ECHOCARDIOGRAM FINDINGS

2D, m-mode, color flow and doppler imaging is available. Diffuse thickening of mitral valve leaflets with no prolapse into the left atrial lumen. Trace/mild eccentric mitral regurgitation with no left atrial dilation. Normal LV diameter with adequate myocardial function. Moderate LV hypertrophy (0.8cm globally) The tricuspid valve appears normal with no tricuspid regurgitation. Normal right atrial and ventricular diameter and morphology indicating no overt evidence of pulmonary arterial hypertension. The pulmonic and aortic valves are normal in morphology and mobility. Normal pulmonic and aortic outflow velocities with laminar flow. No obvious aortic or pulmonic insufficiency. No pericardial or pleural effusion noted. No obvious cardiac masses.

CARDIAC CHART

CANINE CARDIAC PARAMETERS	MR VMAX (m/s)	TR VMAX (m/s)	LA/AO (Boon method)	LA/AO (Heart Base; Swe)	FS (%)	EF (%)	EPSS (cm)
NORMAL PARAMETER	4.5-5.5	<2.7	1.3	<1.6	28-40	40-100	<0.6
PATIENT	NM	NA	1.1	1.0	60	94	NM
CANINE CARDIAC PARAMETERS	HR (BPM)	AV VMAX (m/s)	PV MAX (m/s)	BODY WEIGHT (kg)	LA 2D short axis Base view (cm)	LVIDd Avg; 2D and m-mode short axis (cm)	LVIDs Avg; 2D and m-mode short axis (cm)
NORMAL PARAMETER	50-100	0.7-1.7	0.7-1.6	BELOW	BELOW	BELOW	BELOW
PATIENT	NA	1.6	1.1	2.9	1.2	2.5	1.0
*Normal chamber parameters expressed as a mean value (SD)				3	1.27 (5.3)	2.46 (2.46)	1.36 (5.5)
BODY WEIGHT DEPENDENT PARAMETERS				5	1.40 (4.5)	2.74 (5.2)	1.60 (4.7)
				10	1.50 (3.8)	3.27 (3.5)	2.06 (3.1)
				15	1.83 (2.0)	3.71 (2.4)	2.43 (2.1)
				20	2.02 (1.9)	4.14 (2.2)	2.80 (2.0)
				25	2.18 (2.4)	4.48 (2.9)	3.10 (2.5)

Adapted from June Boon, Veterinary Echocardiography, 1998
 Rishniw M and Hollis NE, J Vet Intern Med 2000; 14:429-435
 Hansson et al, Vet Rad and Ultrasound 2002



PATIENT

Sofie Johnson

Bonagura et al. Echocardiography: principles of interpretation, Vet Clin North Am 15:1177, 1995	30	2.33 (3.3)	4.83 (3.9)	3.39 (3.4)
	35	2.48 (4.3)	5.17 (5.0)	3.69 (4.5)
	40	2.62 (5.2)	5.48 (6.1)	3.96 (5.4)
	50	2.88 (7.1)	6.07 (8.3)	4.46 (7.4)

SPECIES

Canine

BREED

Pomeranian

SEX

Female Spayed

AGE

11 years

WEIGHT

6.5 lbs

INTERPRETED BY

Maggie Machen
Lamy, DVM, DACVIM
(Cardiology)

IMAGING PERFORMED BY

Sara Hansen

HOSPITAL NAME

Willakenzie Animal
Clinic

REFERRING VET

Dr. Kairis

INVOICE

28028

DATE

12/30/22

INTERPRETATION OF THE FINDINGS & FURTHER RECOMMENDATIONS

Chronic degenerative valve disease causing trace/mild mitral regurgitation. Lack of significant left atrial enlargement indicates the current risk for complication is low. The LV does appear significantly hypertrophied, which may reflect volume changes, systemic hypertension, a primary myocardial issue or be a normal variant. A baseline BP is strongly recommended. No additional issues are identified.

Given these findings, the cough is unlikely to be cardiac in origin and primary respiratory causes should be considered. Consider further respiratory work up/treatment (hydrocodone, taper course of steroids, Enrofloxacin, TTW/BAL, etc.). Chronic respiratory disease can lead to development of PAH over time, and monitoring for signs of significantly elevated pulmonary pressures is recommended (exertional dyspnea or syncope).

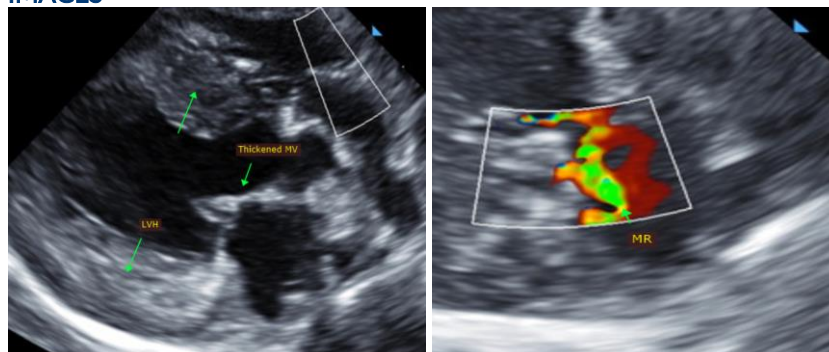
The ECG is most consistent with a respiratory sinus arrhythmia due to high vagal tone. Given the reported cough, in this predisposed breed, this is likely secondary to respiratory disease. Ensure the heart rate stimulates appropriately with exercise/stress. If there is any question, an atropine challenge should be considered.

In a dog with no significant left atrial enlargement, no cardiac medications are clearly indicated. Assessment of progression in the future will help predict long term prognosis, which is highly variable at this stage (B1). Omega fatty acid supplementation and mild salt restriction may be of some long-term benefit. Monitor for development of a cough, labored breathing, exercise intolerance or collapse episodes.

Pending BP assessment, anesthetic risk is considered mild if needed. Premedicate with a vagolytic. Cardiac protective drug choices (opioid/benzodiazepine premedication, propofol or alfaxalone induction, isoflurane gas) are recommended. Pre-oxygenate for 5-10 minutes prior to induction. Monitor for arrhythmias, hypotension, and hypoxia both intra and post-operatively and intervene as necessary. Mild IV fluid restriction is recommended to avoid fluid overload.

Recommend conservative monitoring with a recheck echocardiogram in 6-12 months, sooner if any development of clinical signs.

IMAGES





PATIENT

Sofie Johnson

SPECIES

Canine

BREED

Pomeranian

SEX

Female Spayed

AGE

11 years

WEIGHT

6.5 lbs

INTERPRETED BY

Maggie Machen
Lamy, DVM, DACVIM
(Cardiology)

IMAGING PERFORMED BY

Sara Hansen

HOSPITAL NAME

Willakenzie Animal
Clinic

REFERRING VET

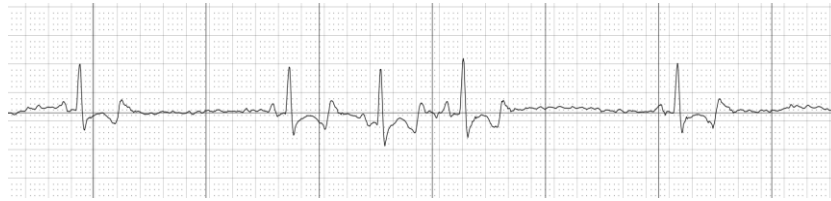
Dr. Kairis

INVOICE

28028

DATE

12/30/22



The information and recommendations provided are based on the images presented by the referring veterinarian. No evaluation can be communicated regarding pathology that was not visible in the image/video clips provided.

Thank you for this referral. This report was generated using transcription software, and minor dictation errors may be present. If the clinical or image interpretation does not parallel your findings or if I can be of any further assistance, please contact me.

Maggie Machen Lamy, DVM
Diplomate of the American College of Veterinary Internal Medicine (Cardiology)
info@sonopath.com